

Case report

Management of colo-adnexal fistula in serous adenocarcinoma of the ovary: a case report

Mohamed Ali Mseddi*, Abdelmalek Mokhtar, Bechir Zahaf, Marwen Ellouze, Rami Guizani, Rakia Siala, Karim Sassi, Mohamed Ben Slima

General Surgery Department, University Hospital La Rabta, Tunis, Tunisia

Abstract

Ovarian cancer is the leading cause of death from gynecological cancer. Fistulization of ovarian cancer into digestive tract with a fistula tract is a rare phenomenon. This complication worsens the prognosis, the fistulous communication in the digestive lumen leads to the leakage of its contents. The tumor therefore becomes superinfected and may result in pelvic peritonitis in case of secondary rupture. On the other hand, the patient is deprived of the benefit of undergoing neoadjuvant chemotherapy, which will decrease the chances of a complete macroscopic cytoreduction. This case presents a 53-year-old patient operated on for a presumed ovarian abscess. Upon exploration, an ovarian tumor fistulized into the sigmoid was discovered. The treatment consisted of sigmoidectomy, creation of an end-loop colostomy, total hysterectomy, bilateral oophorectomy, peritonectomy of 2 pelvic parietal nodules, infra-gastric omentectomy and lombo-aortic curage. The current case highlighted the encountered difficulty on diagnostic and therapeutic levels: the ovarian tumor was misdiagnosed as an abscess and the need of extensive extirpative surgery to comply with “oncological surgery of the ovary” in a hostile environment. Through a literature review, we aim to sensitize the medical community of this rare entity in order to clarify its pathophysiological consequences and make the adequate therapeutic measures.

Keywords: Ovary; Serous Adenocarcinoma; Colon; Digestive; Fistula; Surgery

Received: December 12, 2023; Accepted: January 10, 2024

University Hospital La Rabta, Tunis, Tunisia. mseddibaka@gmail.com

1. Introduction

Ovarian cancer is the leading cause of death from gynecological cancer [1]. Enterogenital fistulas occupy the dominant cause of gynecological fistulas, with the recto-sigmoid colon being the most common site [3]. Fistulae usually occur after previous surgery and chemotherapy, in the setting of relapsed disease rather than as an initial presentation [4]. Spontaneous fistulization of ovarian cancer into digestive tract with a fistula tract is a different and rare phenomenon [5].

Sometimes, the initial diagnosis is misleading, as reported in our case, where the findings were consistent with an intra-abdominal abscess secondary to sigmoid fistula. This is explained by the scarcity of this entity. This complication worsens the prognosis, the fistulous communication in the digestive lumen leads to the leakage of its contents. The tumor therefore becomes superinfected and may result in pelvic peritonitis in case of secondary rupture. On the other hand, the patient is deprived of the benefit of undergoing neoadjuvant chemotherapy, which will decrease the chances of a complete macroscopic cytoreduction.

The purpose of this case report was to clarify its pathophysiological consequences and to outline the best therapeutic approach in this unusual situation.

Written informed consent was obtained from the patient to publish this report in accordance with the journal's patient consent policy.

2. Case presentation

A 53-year-old woman with no medical history, consulted for hypogastric pain of progressive onset for one week. On examination, she was febrile at 39.1°C, abdominal palpation revealed a warm painful mass whose upper limit was abutting the umbilicus. The biology noted a major inflammatory syndrome with WBC=16460/mm³, CRP=340mg/L. The abdominal CT demonstrated a well-limited, partitioned, retro-uterine pelvic mass measuring 200x154mm with an air-liquid level of left ovarian origin.

The patient was shifted to the operating room compound of multidisciplinary team: digestive and gynecological surgeons. Operative findings were as followed: a moderate sero-hemorrhagic effusion, a tumor-like swollen left ovary adherent the last two ileal loops and invading the sigmoid colon with multiple lymph nodes along the inferior mesenteric artery.

During surgery, a hypotensive state occurred, but was manageable with a low dose of catecholamines. Our decision was to provide this patient with the best oncological result with lowest morbidity. This choice was made because if surgery would be delayed second time, formed adhesions

*Correspondence: Mohamed Ali Mseddi, General Surgery Department,

would raise the surgical difficulty. Moreover, second surgery could be non achievable if postoperative complications occur. It was decided to perform an in-toto resection with sigmoidectomy, creation of an end-loop colostomy considering the introduction of noradrenalin and anemia, total hysterectomy, bilateral oophorectomy, peritonectomy of 2 pelvic parietal nodules, infra-gastric omentectomy and lombo-aortic curage; leaving no macroscopic residual pelvic disease. The digestive anastomosis was not performed not to lengthen the operating time and because the patient was anemic.

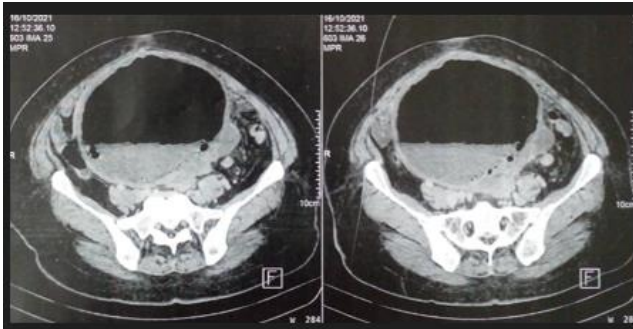


Fig.1. CT slice displaced abscess measuring 200x154mm of left ovarian origin.

After an initial stay in the intensive care unit, she was returned to the ward with successful cessation of catecholamines. Antibiotic therapy was maintained for 7 days with a combination of cefotaxime, metronidazole and gentamicine. The postoperative recovery was without uneventful and the patient was discharged on the 7th of death from gynecological cancer [6]. Early-stage ovarian carcinoma seldom produces symptoms, and consequently more than half of all ovarian carcinomas are at an advanced stage [7].

Although serous adenocarcinoma is the most common histological subtype [6], an exceptional complication has been described. According to a recent literature review by a Japanese team [7], regarding colo-adenexal fistula, only one case was noted with serous carcinoma.

Fistulae usually occur after previous surgery and chemotherapy, in the setting of relapsed disease rather than as an initial presentation [8], spontaneous fistulization of ovarian cancer into digestive tract is a different and rare phenomenon [9]. Enterogenital fistulas occupy the dominant cause of gynecological fistulas, according to a retrospective national Norwegian cohort study of 1627 enrolled women treated for gynecological fistula, whereas urogenital fistulas are the prerogative of post-hysterectomy women [10]. Formation of a fistula to the recto-sigmoid colon, is the most common site [7], accounting for 40% of all involved organs [11].

This complication affects the prognosis. The fistulous communication in the digestive lumen leads to the overflow of it microbial contents. The tumor therefore becomes superinfected and may result in pelvic peritonitis in case of secondary rupture. Surgical treatment therefore becomes unavoidable. On the other hand, the patient is deprived of the benefit of undergoing neoadjuvant chemotherapy, which will decrease the chances of a complete macroscopic cytorreduction. In addition, the operative procedure becomes more laborious: the patient will require segmental colonic resection during the same narcosis.

Trimming then suturing the fistula orifice by the colonic

postoperative day. Histological examination was consistent with a high-grade serous adenocarcinoma infiltrating the colonic wall. She had adjuvant chemotherapy. In the absence of tumor regrowth or secondary localization on the follow-up CT scan, she was scheduled for stoma reversal surgery 5 months later. At follow up consultation three months later, the patient was symptom-free with no evidence of recurrence on CT.

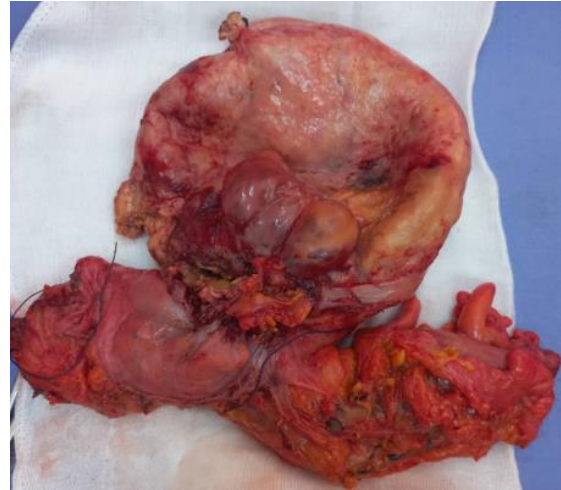


Fig.2. Intraoperative view of enlarged ovary with thickened and irregular wall, collapsed and infiltrating the sigmoid colon

3. Discussion

Ovarian cancer is the leading cause

side seems to us inadequate because it is necessary to perform a monobloc resection in order to comply with the carcinological principles. Moreover, the disconnection of the fistula may induce a spillover of tumor cells into the large peritoneal cavity which will inevitably evolve into a peritoneal miliary. The other issue is the risk of leaking bowel flora contents into the peritoneal cavity. A primary anastomosis is required in favorable conditions. In case of uncompensated hemodynamic state or peritoneal pyostercoral diffusion, transformation into a terminal stoma is the rule. Spontaneous resolution can be awaited with bowel discharge of pus as reported by Kazuoimamura et al. [12], the patient re-consulted only after 46 years after a recrudescence of her symptoms. We cannot count on this eventuality while risking the expansion of suppuration and peritoneal neoplastic graft.

The case reported by Shai et al. [13] demonstrates that a conservative treatment could be undertaken in order to avoid an extensive extirpative surgery and to permit a neoadjuvant treatment, but this eventuality will be validated only if the fistulous track has closed spontaneously, thus requiring a simple separation of the two abutting viscera. However, evidence of fistulous communication may be difficult to obtain with radiological means. Rectal enema is not recommended as it can re-permeabilize or enlarge the visceral communication. Thus, it seems that this attitude could bring more risk than it offers safety. It is true that fistulization does not always imply a tumor invasion, the chronic inflammation inflicted by the iterative twisting attacks or chronic pressure causes this fistulous communication [7]. Nevertheless, considering the high probability of cancerous invasion causing fistulization, reaching up to 38% [11], an en-bloc resection is imperative

in order not to leave a residual neoplastic niche. Finally, considering that concomitant colorectal resection doesn't worsen the prognosis, an optimal resection is the mainstay of available therapeutic tools, as concluded by Fournier[14] where extensive resection has little influence on post-operative morbidity but significantly improves survival.

In conclusion, this clinical case provides insight into a rare complication, which could disrupt the ongoing course of serous adenocarcinoma of the ovary, thus allowing for prompt and appropriate treatment. Based on the current report, we suggest surgery following oncological principles. Delaying anastomosis could be handful in critical patients.

Consent of patient

Written informed consent was obtained from the patient for publication of this case report and any accompanying images.

Funding

None.

Conflict of Interest Disclosures

All authors declare that they have no conflict of interest.

Authors' contributions

All authors have read and agreed to the published version of the manuscript.

References

[1] Mederos N, Wolfer A, Mathevet P, Zaher M, Sarivalasis A. Le cancer séreux de haut grade de l'ovaire en 2018 : avancées et controverses. *Rev Med Suisse*. 2018;14(607):1037-41. <https://doi.org/10.53738/REVMED.2018.14.607.1037>.

- [2] Kizaki Y, Nagai T, Ohara K, Gomi Y, Akahori T, Ono Y, et al. Ovarian mature cystic teratoma with fistula formation into the rectum: a case report. *SpringerPlus*. 2016;5(1):1700. <https://doi.org/10.1186/s40064-016-3426-4>.
- [3] Sfakianos GP, Numnum TM, Halverson CB, Panjeti D, Kendrick 4th JE, Straughn JrM. The risk of gastrointestinal perforation and/or fistula in patients with recurrent ovarian cancer receiving bevacizumab compared to standard chemotherapy: A retrospective cohort study. *Gynecol Oncol*. 2009;114:424-6. <https://doi.org/10.1016/j.ygyno.2009.05.031>.
- [4] Yahagi N, Kobayashi Y, Ohara T, Suzuki N, Kiguchi K, Ishizuka B. Ovarian carcinoma complicated by sigmoid colon fistula formation: a case report and review of the literature: colon fistula formation. *J Obstet Gynaecol Res*. 2011;37(3):250-3. <https://doi.org/10.1111/j.1447-0756.2010.01341.x>.
- [5] Ureyen I, Toptas T, Tatar SA, Ekin G, Gulec F, Uysal A. Jejunal fistula complicating ovarian serous carcinoma: case report of a rare phenomenon and review of the literature. *Gynecol Obstet Reprod Med*. 2021;27(2):184-6. <https://doi.org/10.21613/GORM.2018.816>.
- [6] Børseth KF, Acharya G, Kiserud T, Trovik J. Incidence of gynecological fistula and its surgical treatment: a national registry-based study. *Acta Obstet Gynecol Scand*. 2019;98(9):1120-6. <https://doi.org/10.1111/aogs.13611>.
- [7] Imamura K, Nishimura H, Takao M, Maruuchi T, Ogou Y, Kiyozuka Y, et al. Ovarian tumor complicated by a colo-ovarian fistula. *Oncol Rep*. 1997;4(6):1277-9. <https://doi.org/10.3892/or.4.6.1277>.
- [8] Shai A, Grikshtas E, Segev Y, Moskovitz M, Bitterman A, Steiner M, et al. Conservative management for an entero-adnexal fistula at initial presentation of advanced ovarian carcinoma. *Curr Oncol*. 2013;20(1):44-7. <https://doi.org/10.3747/co.20.1196>.
- [9] Fournier M. Morbidité des résections recto-sigmoïdiennes dans la chirurgie de cytoréduction des cancers de l'ovaire. Dissertation, Faculté de Médecine PARIS DESCARTES, 2015.

Cite this article as: Mseddi MA, Mokhtar A, Zahaf B, Ellouze M, Guizani R, Siala R, Sassi K, Ben Slima M. Management of colo-adnexal fistula in serous adenocarcinoma of the ovary: a case report. *Biomedicine Healthcare Res*. 2024;2:42-44. <https://doi.org/10.5281/zenodo.10570028>