

## Case report

# Familial medullary thyroid carcinoma: A rare germline mutation in the *RET* proto-oncogene

Fatima Maarouf<sup>1\*</sup>, Amal Tazzite<sup>2,3</sup>, Hind Dehbi<sup>1,2</sup><sup>1</sup>Laboratory of Medical Genetics, Ibn Rochd University Hospital, Casablanca, Morocco<sup>2</sup>Laboratory of Cellular and Molecular Pathology, Faculty of Medicine and Pharmacy of Casablanca, Hassan II University, Casablanca, Morocco<sup>3</sup>Higher Institute of Nursing Professions and Health Techniques of Casablanca, Morocco**Abstract**

Medullary thyroid carcinoma (MTC) is an aggressive thyroid cancer that generally accounts for more than 10% of thyroid malignancies. Approximately 25% of MTC cases exhibit up hereditary traits. Dominantly inherited syndromes of MTC such as multiple endocrine neoplasia type 2A (MEN 2A), multiple endocrine neoplasia type 2B (MEN 2B) and familial medullary thyroid carcinoma (FMTC) are linked to gain-of-function alterations in the *RET* proto-oncogene. This latter encodes a receptor tyrosine kinase involved in several signal transduction pathways in neural precursor cells. Therefore, genetic screening for *RET* mutations facilitates early disease diagnosis and the possibility of prophylactic thyroidectomy for at-risk relatives. This study underscores the relevance of *RET* genetic analysis by describing a familial case of MTC with c.1597G>T (p.Gly533Cys) mutation in the *RET* gene.

**Keywords:** Medullary thyroid carcinoma; RET proto-oncogene; Familial medullary thyroid carcinoma

Received: December 16, 2023; Accepted: January 10, 2024.

Hospital Center, Casablanca, Morocco. Email: [maaroufcadem@gmail.com](mailto:maaroufcadem@gmail.com)

**1. Introduction**

Medullary thyroid carcinoma (MTC) is an uncommon neuroendocrine malignancy that accounts for 5 to 10% of thyroid tumors [1]. It is responsible for 13.4% of all deaths from thyroid cancer [2]. Almost, 75% of patients exhibit sporadic forms of MTC (resulting from de novo *RET* mutations) and the remaining 25% have MTC associated with multiple endocrine neoplasia type 2 (MEN2) syndrome [3]. Three MEN2 subtypes, MEN2A, MEN2B, and familial medullary thyroid carcinoma (FMTC), have been defined based on the clinical characteristics of the patients [4]. MEN2A is characterized by the presence of MTC and pheochromocytoma often associated with adenoma of the parathyroids and rarely with Hirschsprung's disease, cutaneous lichen, as well as amyloidosis [1]. On the other side, MEN2B is characterized by the coexistence of MTC and pheochromocytoma with other clinical manifestations resembling those seen in individuals with Marfan syndrome. Sensory nerve impairments and megacolon are also present without hyperparathyroidism [4]. In some cases, MTC manifests in isolation (FMTC). The three MEN2 subtypes are inherited in an autosomal dominant manner [5] and the prognosis hinges on tumor stage, gender, age and classification [2,6].

The Rearranged during Transfection (*RET*) proto-oncogene, that contains 21 exons, is located on chromosome 10q11.2 and encodes a receptor tyrosine kinase [7]. The expression of the RET protein is specifically confined to a select group of adult neural crest-derived cells (thyroid C-

Cells and medullary chromaffin cells). In these tissues, *RET* gene has a pivotal role in governing cell proliferation, development, differentiation, migration, survival and apoptosis [7]. Thereby, alterations in the *RET* proto-oncogene can result in thyroid malignancy [1]. The extracellular domain of the RET protein contains regions homologous with the cadherin family and a significant cysteine-rich sequence [6]. Genetic and epigenetic alterations of the *RET* gene are of crucial significance. Indeed, they have been reported to be unfavorable prognostic factors [8]. Furthermore, other mutations contribute to the MTC pathogenesis and genotype-phenotype correlation [12]. This case report describes a Moroccan familial case of MTC with a germline mutation in the *RET* proto-oncogene.

**2. Case report**

Fig.1 depicts the pedigree of the current Moroccan family. The index case (III.2; Fig.1) is a 47-year-old woman, married and mother of two children, with a history of left ovariectomy 20 years ago due to an ovarian cyst. Asymptomatic until the age of 42, she observed a thyroid nodule in the left lobe without signs of thyroid dysfunction or compressive symptoms, alongside a history of flush syndrome. A thyroid ultrasound revealed two thyroid nodules in the left lobe with left cervical lymphadenopathy. The baseline serum calcitonin level was 870 pg/ml (Reference range: <11.5 pg/ml), and the TSH level was 0.67  $\mu$ UI/ml (Reference range: between 0.34 and 5.60  $\mu$ UI/ml).

\*Corresponding author: Dr. Fatima Maarouf, Ibn Rochd University

Total thyroidectomy was performed with retrospinal jugularocrotid and supraomohyoid lymph node dissection.

Pathological and immunohistochemical examination revealed medullary thyroid carcinoma, with no evidence of nodal metastasis or residual tumor. A genetic study was initiated using the Sanger sequencing method in order to analyze multiple exons of the *RET* gene (RefSeq NM\_020975, including exons 5, 8, 9, 10, 11, 13, 14, 15, 16). This analysis confirmed the presence of a heterozygous mutation c.1597G>T (p.Gly533Cys) in exon 8 of *RET* gene. Subsequently, the diagnosis was confirmed through a detailed analysis of only exon 8 using Sanger sequencing on a second blood sample.

The proband's mother (II.2; Fig.1), a 70-year-old woman, as well as her older sister aged 50 (III.1. Fig.1) and her 35-year-old brother (II.5; Fig.1) affected by MTC, all carried the same heterozygous mutation in the *RET* gene. However, the affected sister (III.3; Fig.1) aged 38 had not yet undergone genetic testing. Concerning the other two brothers (III.4 and III.6; Fig.1), they are unaffected and asymptomatic, and they have not yet initiated any genetic investigation.

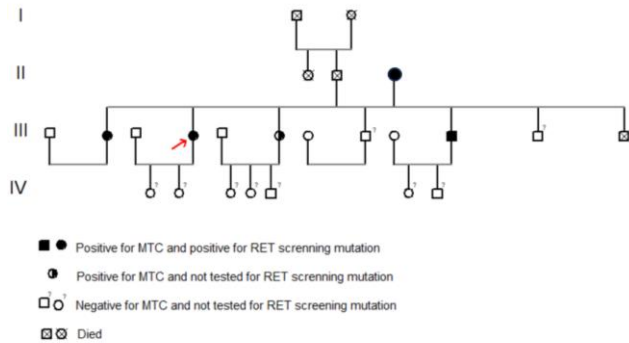


Fig.1. Pedigree of the present family with MTC. (Circles represent females, squares represent males and filled circles indicate individuals with the disease).

#### 4. Discussion

FMTC typically presents as bilateral and multifocal lesions accompanied by hyperplasia of C cells. Moreover, it is characterized by the deposit of amyloid in the tumor [8]. The clinical diagnosis of FMTC is established when at least four members of the same family, belonging to different age groups, present with MTC [9]. However, family history may be insufficient for FMTC diagnosis. Therefore, genetic and biochemical examinations are strongly recommended. To date, germline mutations in the *RET* proto-oncogene have been identified in a significant proportion of families affected by MEN2 ( $\approx 98\%$ ) and FMTC (88%) [10]. MEN2A syndrome was associated with *RET* mutations predominantly located in the extracellular cysteine-rich domain of the protein which is encoded by exons 10 and 11 (Cys609Arg; Cys611Ser; Cys618Phe; Cys620Tyr; Cys634Arg). However, the majority of patients with MEN2B harbor Met918Thr mutation within exon 16 which encodes the tyrosine kinase domain [11]. Regarding FMTC patients, most mutations involved cysteine codons of exons 10 and 11 [12,13]. Recently, it was suggested that microRNAs could participate to MTC development [14].

In this study, a rare germline mutation was identified in exon 8 of the *RET* gene specifically at codon 533. Previously, a singular mutation has been detected in exon 8 of the *RET* gene in an FMTC family [7]. It consists in 9-base pair duplication leading to the addition of a cysteine amino acid. Moreover, a novel *RET* missense mutation has been reported in exon 8 (p.Gly533Cys) in a large Brazilian family. It occurs in the same region as the previous mutation [7]. Considering these results, this mutation could be causal for FMTC. However, it is necessary to extend genetic investigations to this specific mutation region. Consequently, a comprehensive follow-up of these cases is essential for a better understanding of this mutation carrier's prognosis.

*RET* genetic screening is a valuable tool in the diagnosis of MTC. Nevertheless, a systematic approach centered on family investigation is indispensable. The definitive diagnosis relies on molecular analysis of the *RET* gene. This analysis, conducted from a blood sample, required a patient written informed consent. The genetic testing specifically targets seven hotspot exons of the *RET* gene namely exons 8, 10, 11, 13, 14, 15, and 16. In the majority of cases (95%), the identification of *RET* mutations allows MEN2 diagnosis [15] (Fig. 2). Nevertheless, it is important to emphasize that the absence of mutations cannot formally exclude FMTC.

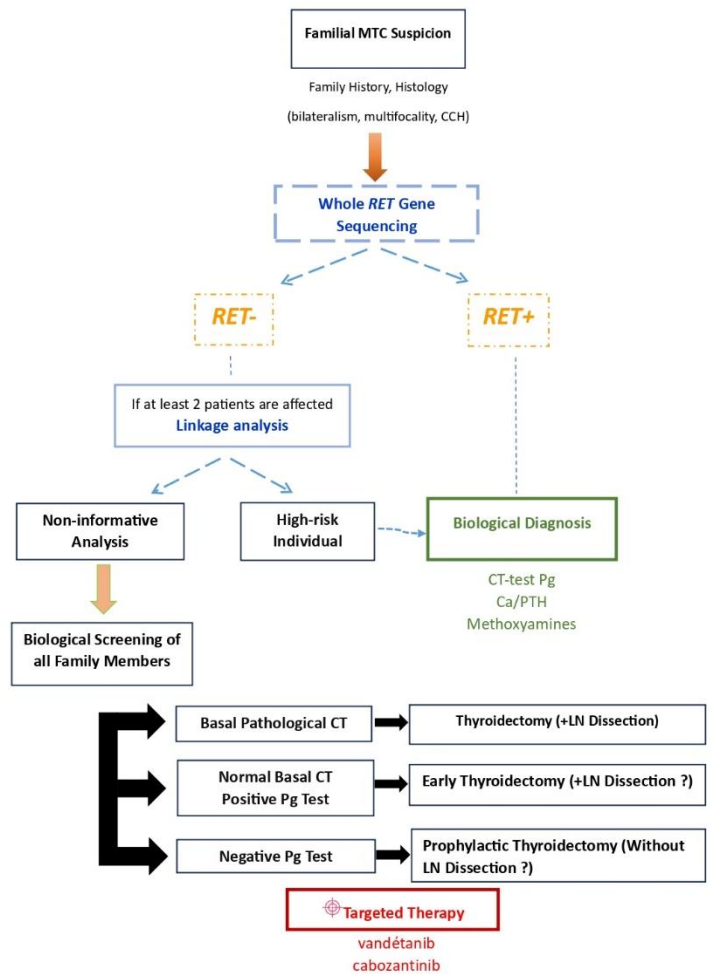


Fig.2. Screening strategy for familial medullary thyroid cancer HCC: C cell hyperplasia; CT: Calcitonin (tumor marker); Test Pg: Pentagastrin stimulation test; Ca/PTH: Calcium/Parathyroid Hormone; LN Dissection: Lymph Node Dissection.

In the context of familial cases of MTC or FMTC with multifocal, bilateral features and bilateral C-cell hyperplasia, complete sequencing of the *RET* gene is recommended to identify potential mutations in the other exons of the gene. In the case of a negative result despite a clear familial context, the diagnosis of MEN2 relies on the analysis of genetic polymorphism through a linkage study conducted in the index case and their related members. This study necessitates the involvement of at least two affected and two unaffected individuals. In all suspected cases without genetic confirmation, it is necessary to investigate other components of MEN2 in the proband and at-risk members, both initially and throughout clinical follow-up (16). This process facilitates the monitoring of patients for the detection of associated pathologies. Additionally, screening and preventive treatment through prophylactic thyroidectomy before the onset of MTC are recommended for at-risk family members [17]. Surgery alone or combined with traditional chemotherapy is not effective for the treatment of MTC. Therefore, there is a recognized need for a targeted therapeutic approach. To date, two targeted therapies (vandetanib and cabozantinib) have been approved by the U.S. Food and Drug Administration [18,19]. Both are tyrosine kinase inhibitors (TKIs) used to treat symptomatic, advanced, or progressing MTC. However, the response to TKIs may vary according to the tumor mutational status, highlighting the need for additional data to assess the efficacy of these treatments [20].

In conclusion, It is highly recommended to conduct the analysis of exon 8 of the *RET* gene in families affected by familial MTC. Otherwise, next-generation sequencing provides in-depth analysis of molecular alterations, which facilitates the identification of patients at higher risk.

### Consent of patient

Written informed consent was obtained from the patient for publication of this case report and any accompanying images.

### Funding

None.

### Conflict of Interest Disclosures

All authors declare that they have no conflict of interest.

### Authors' contributions

MF and DH carried out the collection of family data, clinical and para-clinical examination, and the drafting of the initial manuscript. HD, MF, and TA performed the data analysis and interpretation. Drafting of the manuscript was done by MF. HD coordinated and supervised data collection, reviewed and revised the manuscript. TA reviewed and revised the manuscript. All authors contributed to the article and approved the submitted version.

### References

- [1] Accardo G, Conzo G, Esposito D, Gambardella C, Mazzella M, Castaldo F, et al. Genetics of medullary thyroid cancer: An overview. *Int J Surg*. 2017;41:S2-6. <https://doi.org/10.1016/j.ijsu.2017.02.064>.
- [2] Hyer SL, Vini L, A» Hern R, Harmer C. Medullary thyroid cancer: multivariate analysis of prognostic factors influencing survival. *Eur J Surg Oncol EJSO*. 2000;26(7):686-90. <https://doi.org/10.1053/ejs.2000.0981>.
- [3] Fagin JA, Wells SA. Biologic and clinical perspectives on thyroid cancer. *N Engl J Med*. 2016;375(11):1054-67. <https://doi.org/10.1056/NEJMra1501993>.
- [4] Confer A, Owston MA, Kumar S, Dick EJ Jr. Multiple endocrine neoplasia-like syndrome in 24 baboons (*Papio spp.*). *J Med Primatol*. 2018;47(6):434-439. Epub 2018 Sep 6. <https://doi.org/10.1111/jmp.12376>.
- [5] Modigliani E, Cohen R, Campos JM, Conte-Devolx B, Maes B, Boneu A, et al. Prognostic factors for survival and biochemical cure in medullary thyroid carcinoma: results in 899 patients. The GETC Study Group. *Groupe d'étude des tumeurs à calcitonine*. *Clin Endocrinol (Oxf)*. 1998;48(3):265-73. <https://doi.org/10.1046/j.1365-2265.1998.00392.x>.
- [6] Kameyama K, Okinaga H, Takami H. RET oncogene mutations in 75 cases of familial medullary thyroid carcinoma in Japan. *Biomed Pharmacother*. 2004;58(6):345-7. <https://doi.org/10.1016/j.biopha.2004.05.001>.
- [7] RET in breast cancer: pathogenic implications and mechanisms of drug resistance. *Cancer Drug Resist*. 2019;2(4):1136-52. <https://doi.org/10.20517/cdr.2019.66>.
- [8] Roman S, Lin R, Sosa JA. Prognosis of medullary thyroid carcinoma: demographic, clinical, and pathologic predictors of survival in 1252 cases. *Cancer*. 2006;107(9):2134-42. <https://doi.org/10.1002/cncr.22244>.
- [9] American Thyroid Association Guidelines Task Force, Kloos RT, Eng C, Evans DB, Francis GL, Gagel RF, et al. Medullary thyroid cancer: management guidelines of the American Thyroid Association. *Thyroid* 2009;19(6):565-612. <https://doi.org/10.1089/thy.2008.0403>.
- [10] Khurana R, Agarwal A, Bajpai VK, Verma N, Sharma AK, Gupta RP, et al. Unraveling the amyloid associated with human medullary thyroid carcinoma. *Endocrinology*. 2004;145(12):5465-70. <https://doi.org/10.1210/en.2004-0780>.
- [11] Hedayati M, Zarif Yeganeh M, Sheikhol Eslami S, Rezghi Barez S, Hoghooghi Rad L, Azizi F. Predominant RET Germline Mutations in Exons 10, 11, and 16 in Iranian Patients with Hereditary Medullary Thyroid Carcinoma. *J Thyroid Res*. 2011;2011:264248. <https://doi.org/10.4061/2011/264248>.
- [12] Margraf RL, Mao R, Highsmith WE, Holtegaard LM, Wittwer CT. RET proto-oncogene genotyping using unlabeled probes, the masking technique, and amplicon high-resolution melting analysis. *J Mol Diagn*. 2007;9(2):184-96. <https://doi.org/10.2353/jmoldx.2007.060091>.
- [13] Santos MACGD, Quedas EPDS, Toledo RDA, Lourenço-Júnior DM, Toledo SPDA. Screening of RET gene mutations in multiple endocrine neoplasia type-2 using Conformation Sensitive Gel Electrophoresis (CSGE). *Arq Bras Endocrinol Metabol*. 2007;51(9):1468-76. <https://doi.org/10.1590/s0004-27302007000900009>.
- [14] Figlioli G, Landi S, Romei C, Elisei R, Gemignani F. Medullary thyroid carcinoma (MTC) and RET proto-oncogene: Mutation spectrum in the familial cases and a meta-analysis of studies on the sporadic form. *Mutat Res*. 2013;752(1):36-44. <https://doi.org/10.1016/j.mrrev.2012.09.002>.
- [15] Da Silva AMA, Maciel RMB, Da Silva MRD, Toledo SRC, De Carvalho MB, Cerutti JM. A novel germ-line point mutation in RET exon 8 (Gly(533)Cys) in a large kindred with familial medullary thyroid carcinoma. *J Clin Endocrinol*

- Metab. 2003;88(11):5438-43. <https://doi.org/10.1210/jc.2003-030997>.
- [16] Hoff AO, Cote GJ, Gagel RF. Multiple endocrine neoplasias. *Annu Rev Physiol.* 2000;62(1):377-411. <https://doi.org/10.1146/annurev.physiol.62.1.377>.
- [17] Cantisani V, Grazhdani H, Ricci P, Morteale K, Di Segni M, D'Andrea V, et al. Q-Elastosonography of solid thyroid nodules: assessment of diagnostic efficacy and interobserver variability in a large patient cohort. *Eur Radiol.* 2014;24(1):143-50. <https://doi.org/10.1007/s00330-013-2991-y>.
- [18] Elisei R, Schlumberger MJ, Müller SP, Schöffski P, Brose MS, Shah MH, et al. Cabozantinib in progressive medullary thyroid cancer. *J Clin Oncol* 2013;31(29): 3639-46. <https://doi.org/10.1200/JCO.2012.48.4659>.
- [19] Wells SA, Robinson BG, Gagel RF, Dralle H, Fagin JA, Santoro M, et al. Vandetanib in patients with locally advanced or metastatic medullary thyroid cancer: a randomized, double-blind phase III trial. *J Clin Oncol.* 2012;30(2):134-41. <https://doi.org/10.1200/JCO.2011.35.5040>.
- [20] Xuefang Hu, Jian Guan, Yangdi Wang, Siya Shi, Chenyu Song, Zi-Ping Li, Shi-Ting Feng, et al. A narrative review of multiple endocrine neoplasia syndromes: genetics, clinical features, imaging findings, and diagnosis. *Ann Transl Med.* 2021;9(11):944. <https://doi.org/10.21037/atm-21-1165>.

Cite this article as: Maarouf F, Tazzite A, Dehbi H. Familial medullary thyroid carcinoma: A rare germline mutation in the *RET* proto-oncogene. *Biomedicine Healthcare Res.* 2024;2:35-38. <https://doi.org/10.71599/bhr.v2i1.78>