

Case report

Chest wall Desmoid tumor...A multidisciplinary care

Ferial Souissi^{1*}, Taieb Cherif¹, Nidhal Mahdhi², Imene Mgarrech¹, Mohamed Chokri Kortas¹, Sofienne Jerbi¹¹Department of thoracic and cardiovascular surgery, Sahloul University Hospital, Sousse, Tunisia²Department of Plastic Surgery Sahloul University Hospital, Sousse, Tunisia**Abstract**

Desmoid tumors, though rare, can present challenges, especially when occurring in the chest. This case involves a 44-year-old woman with a parietal swelling, initially painless but progressively growing. "Café au lait" spots were noted, along with a left paraspinal mass. Imaging revealed an infiltrating parasternal mass extending to adjacent structures. An ultrasound-guided biopsy confirmed the diagnosis of desmoid type fibromatosis. After initial monitoring, surgery became indicated due to tumor growth. The patient had a total en bloc resection of the tumor process taking out the anterior arches of the 3rd to the 5th left rib with their intercostal spaces, the lower and left part of the sternal body as well as the xiphoid appendage. A polypropylene plate was used to construct the parietal defect. In order to cover the loss of soft tissue, a myoplasty with a pure and pedicle left pectoralis major muscle flap was performed. The final anatomic-pathological examination of the specimen concluded to a complete resection of the tumor with healthy margins. The patient's postoperative course was uncomplicated with no local recurrence after 12 months. Despite the benignity of desmoid tumors, they do represent a real local danger considering their aggressiveness. The tumor resection must be complete with adequate margins in order to decrease the risk of local recurrence.

Keywords: Desmoid Tumor; Case report; Chest wall; Surgery; Multidisciplinary care

Received: December 15, 2023; Accepted: January 19, 2024

1. Introduction

Desmoid tumors, also known as aggressive fibromatoses, account for 3.5% of all fibrous tumors [1]. These rare tumors are highly invasive and recurrent but without metastatic potential. Uncommon in the chest, they pose diagnostic and therapeutic challenges [1]. Diagnosis relies on anatomic-pathological examination, guided by thoracic CT and MRI.

The management of this type of tumor represents a challenge. Indeed, the way in which these tumors are treated has changed over the years. While "Active monitoring" is favored [2], surgery is considered for locally advanced cases. In these cases, resection is often extensive and complex parietal reconstruction may be necessary. Adjuvant radiotherapy and non-steroidal anti-inflammatory treatments are other options.

2. Case report

We report the case of a 44-year-old woman, without any notable pathological history, who presented with growing parietal swelling. It was a left basithoracic swelling that has rapidly increased in size. The examination showed multiple "café au lait" spots (Fig.1) spread over the whole body with a left anterior paraspinal mass, solid, fixed to the deep plane, painless, without signs of inflammation. The thoracic MRI showed a four-centimeter left anterior paraspinal thoracic infiltrating mass with extension to the anterior arches of the 4th rib (Fig.2).

*Correspondence: Dr. Ferial Souissi, Department of Thoracic and Cardiovascular Surgery, Sahloul University Hospital, Sousse, Tunisia. ferielsouissi21@gmail.com

An ultrasound-guided biopsy was performed and the anatomic-pathological study of the specimens concluded to a desmoid type fibromatosis. The decision was to initially monitor the patient, but the evolution was marked by an increase in size and the mass became increasingly painful.

One month later, the patient was operated on. Through an elective incision (Fig.3), she had a total en bloc resection of the tumor taking out the anterior arches of the 3rd to the 5th left rib with their intercostal spaces, the lower and left part of the sternal body as well as the xiphoid appendage (Fig.4).

A polypropylene plate was used to construct the parietal defect (Fig.5A). In order to cover the soft tissue loss, a myoplasty with a pure and pedicle left pectoralis major muscle flap was performed (Fig.5B). The postoperative course was uneventful and the patient was discharged at 8 days postoperatively.

The final anatomic-pathological examination of the specimen concluded to a complete resection of the tumor with healthy margins. At 12-month follow-up, no local recurrence has been noted.

3. Discussion

Desmoid tumors, first described in 1832, are locally aggressive [3]. Macroscopically, desmoid tumors are hard and firm, gray or whitish in color. Microscopically, the cells are characterized by heterogeneous, ill-defined and uniform proliferation of spindle cells reflecting myofibroblasts enveloped in an abundant collagen stroma and a capsule-free vascular network. There is no atypia, necrosis or mitosis [3].

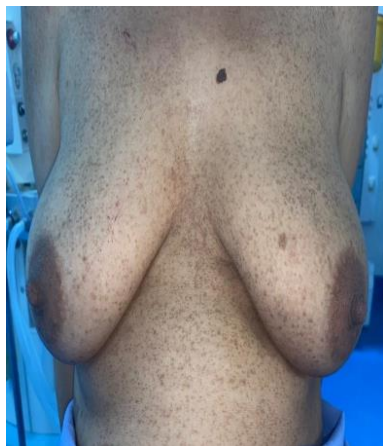

Fig. 1. 'Café au lait' spots

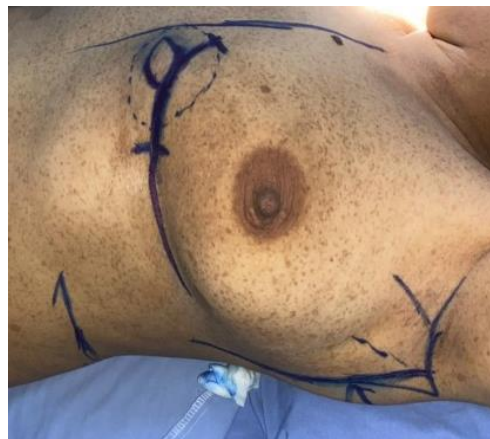

Fig. 3. Limits of the surgical incision

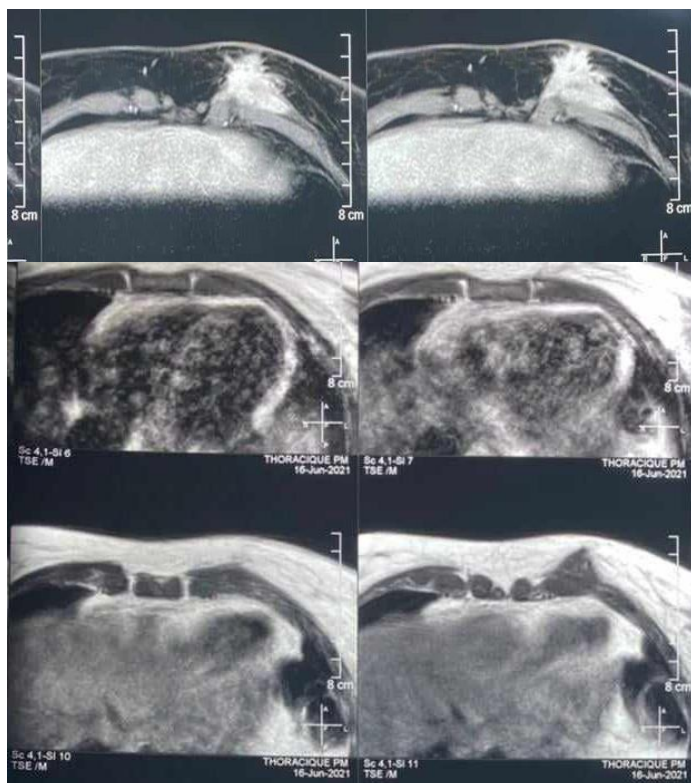


Fig. 2. The thoracic MRI showing the tumor mass

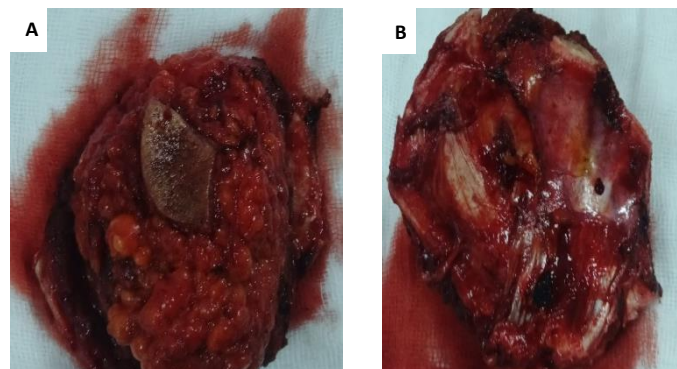


Fig. 4. Photo of the specimen (A: Anterior view/ B: posterior view)

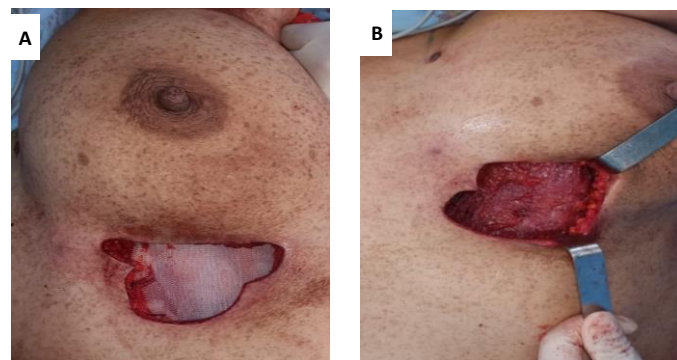


Fig. 5. (A) The coverage of the parietal defect with a polypropylene plate. (B) The coverage of the soft tissue defect with a left pectoralis major muscle flap

These tumors are predominantly seen in young females, with an average age ranging between 30 and 40 [4]. As they can be asymptomatic, desmoid tumors can be disabling. This depends on their location [3].

Radiological investigations, such as thoracic CT and thoracic MRI, are crucial for diagnosis and follow-up [3,5]. The diagnosis of desmoid tumor can only be confirmed by pathological examination of a transparietal or open biopsy. Needle biopsy seems to be the most commonly used method [6,7].

The evolution of desmoid tumors is unpredictable. As they may regress spontaneously, they may become locally aggressive. Surgical treatment has long been considered the reference and 1st-line treatment for these tumors. However, in recent years, the therapeutic strategy has changed, and surgery is no longer the 1st-line treatment. Today, surgical treatment is reserved for invasive forms or localizations that

could jeopardize vital or functional prognosis [2,6-9].

In this case, surgery can only be performed when it is not risky and when complete resection with healthy margins is guaranteed [1,7,10-12]. Desmoid tumors are characterized by a local recurrence rate of 20 to 65% within 5 years [1,13,14]. Thus, local recurrence remains a concern. The three golden rules for surgery of desmoid tumors are: a complete and carcinologically satisfactory resection, an adequate parietal repair to restore normal respiratory function and a coverage by good quality of flaps [15-18].

For resections with healthy margins, adjuvant radiotherapy has shown no difference in the control of local recurrences compared to surgery alone [2,6,13]. Hence, for the patients operated on for desmoid tumor with R0 resection, regular monitoring is all that's needed [1]. However, for R1 and R2 resections, radiotherapy is essential. It is recommended at a dose of 50-56 Gy. It is also

recommended in the event of local recurrence [19]. As for chemotherapy, it is indicated for tumors with rapid evolution and for tumors of critical location [19]. Moreover, some non-steroidal anti-inflammatory treatments have shown efficacy in the treatment of desmoid tumors [1,20].

In conclusion, despite their benign nature desmoid tumors pose a local threat and require careful management. In fact, they are known by their slow progressive growth, their local invasion as well as their local recurrence after excision with no metastatic potential. The 'Wait and see' approach is recommended, and if surgery is indicated, complete and satisfying resection is crucial to minimize local recurrence risk.

Consent of patient

Written informed consent was obtained from the patient for publication of this case report and any accompanying images.

Funding

None.

Conflict of Interest Disclosures

All authors declare that they have no conflict of interest.

Authors' contributions

The patient was operated by TC, NM and FS. Drafting of the manuscript was done by FS. The manuscript was corrected by IM, CK and SJ. All authors have read and agreed to the published version of the manuscript.

References

[1] Xiao Y, He J, Gong C, Liu L, Huang S. Desmoid-type fibromatosis of the chest wall: a case report. *Ann Transl Med* 2020;8:1322–1322. <https://doi.org/10.21037/atm-20-5237>.

[2] Kasper B, Baumgarten C, Garcia J, Bonvalot S, Haas R, Haller F, et al. An update on the management of sporadic desmoid-type fibromatosis: a European Consensus Initiative between Sarcoma PATients EuroNet (SPAEN) and European Organization for Research and Treatment of Cancer (EORTC)/Soft Tissue and Bone Sarcoma Group (STBSG). *Ann Oncol* 2017;28:2399–408. <https://doi.org/10.1093/annonc/mdx323>.

[3] Garcia-Ortega DY, Martín-Tellez KS, Cuellar-Hubbe M, Martínez-Said H, Álvarez-Cano A, Brener-Chaoul M, et al. Desmoid-Type Fibromatosis. *Cancers* 2020;12:1851. <https://doi.org/10.3390/cancers12071851>.

[4] Kasper B, Ströbel P, Hohenberger P. Desmoid Tumors: Clinical Features and Treatment Options for Advanced Disease. *Oncologist* 2011;16:682-93. <https://doi.org/10.1634/theoncologist.2010-0281>.

[5] Grubstein A, Rapson Y, Zer A, Gadiel I, Atar E, Morgenstern S, et al. MRI diagnosis and follow-up of chest wall and breast desmoid tumours in patients with a history of oncologic breast surgery and silicone implants: A pictorial report. *J Med Imag Rad Onc* 2019;63:47–53. <https://doi.org/10.1111/1754-9485.12829>.

[6] Penel N, Le Cesne A, Bonvalot S, Giraud A, Bompas E, Rios M, et al. Surgical versus non-surgical approach in primary desmoid-type fibromatosis patients: A nationwide prospective cohort from the French Sarcoma Group. *Eur J Cancer* 2017;83:125–31. <https://doi.org/10.1016/j.ejca.2017.06.017>.

[7] Ganeshan D, Amini B, Nikolaidis P, Assing M, Vikram R. Current Update on Desmoid Fibromatosis. *J Comput Assist Tomogr* 2019;43:29–38. <https://doi.org/10.1097/RCT.0000000000000790>.

[8] Bonvalot S, Eldweny H, Haddad V, Rimareix F, Missenard G, Oberlin O, et al. Extra-abdominal primary fibromatosis: Aggressive management could be avoided in a subgroup of patients. *European J Surg Oncol (EJSO)* 2008;34:462–8. <https://doi.org/10.1016/j.ejso.2007.06.006>.

[9] Alman B, Attia S, Baumgarten C, Benson C, Blay J-Y, Bonvalot S, et al. The management of desmoid tumours: A joint global consensus-based guideline approach for adult and paediatric patients. *Eur J Cancer* 2020;127:96–107. <https://doi.org/10.1016/j.ejca.2019.11.013>.

[10] Wong SL. Diagnosis and management of desmoid tumors and fibrosarcoma. *J Surg Oncol* 2008;97:554–8. <https://doi.org/10.1002/jso.20981>.

[11] Luo Y, Yang R, Ji P, Yang Y. Giant desmoid fibromatosis in chest wall: A case report. *Asian J Surgery* 2022;45:1322–3. <https://doi.org/10.1016/j.asjsur.2022.01.049>.

[12] Ong Q, Wong J, Sinha S, Kejrival N. Desmoid fibromatosis of the chest wall. *Respirol Case Reports* 2018;6:e00310. <https://doi.org/10.1002/rcr2.310>.

[13] Bonvalot S, Desai A, Coppola S, Le Péchoux C, Terrier P, Dômont J, et al. The treatment of desmoid tumors: a stepwise clinical approach. *Ann Oncol* 2012;23:x158–66. <https://doi.org/10.1093/annonc/mds298>.

[14] Zizzo M, Castagnetti F, Valli R, Bellafiore S, Borrelli R, Di Stefano T, et al. Dramatic progression of a chest wall desmoid-like fibromatosis. *ANZ J Surg* 2019;89. <https://doi.org/10.1111/ans.14859>.

[15] Ver Halen JP, Soto-Miranda MA, Sandoval JA. Reconstruction of Desmoid Tumors: Case Series and Systematic Review. *Ann Plastic Surg* 2015;75:480–6. <https://doi.org/10.1097/SAP.000000000000129>.

[16] Salo JTK, Tukiainen EJ. Oncologic resection and reconstruction of the chest wall: A 19-year experience in a single center. *Plastic Reconstr Surg* 2018;142:536–47. <https://doi.org/10.1097/PRS.0000000000004597>.

[17] Althubaiti G, Butler CE. Abdominal Wall and Chest Wall Reconstruction: Plastic Reconstr Surg 2014;133:688e–701e. <https://doi.org/10.1097/PRS.000000000000086>.

[18] Tukiainen E. Chest Wall Reconstruction after Oncological Resections. *Scand J Surg* 2013;102:9–13. <https://doi.org/10.1177/145749691310200103>.

[19] Martínez Trufero J, Pajares Bernad I, Torres Ramón I, Hernando Cubero J, Pazo Cid R. Desmoid-Type Fibromatosis: Who, When, and How to Treat. *Curr Treat Options Oncol* 2017;18:29. <https://doi.org/10.1007/s11864-017-0474-0>.

[20] Signoroni S, Frattini M, Negri T, Pastore E, Tamborini E, Casieri P, et al. Cyclooxygenase-2 and Platelet-Derived Growth Factor Receptors as Potential Targets in Treating Aggressive Fibromatosis. *Clin Cancer Res* 2007;13:5034–40. <https://doi.org/10.1158/1078-0432.CCR-07-0336>.

Cite this article as: Souissi F, Cherif T, Mahdhi N, Mgarrech I, Kortas C, Jerbi S. Chest wall desmoid tumor...a multidisciplinary care. *Biomedicine Healthcare Res.* 2024;2:47-49. <https://doi.org/10.5281/zenodo.10570042>

